

## Case Report

# Digital and Conventional Approach for the Treatment of Severe Anterior Dental Wear in a Type 2 Diabetes Patient

Raul Rotar, Codruta Ilie\*, Anca Jivanescu

Department of Prosthodontics, “Victor Babes” University of Medicine and Pharmacy Timisoara, Romania

\*Correspondence to: Codruta Ilie, Department of Prosthodontics, “Victor Babes” University of Medicine and Pharmacy Timisoara, Romania, E-mail: codrutaille@yahoo.com, Phone: +40746382959

Received: 22 April 2020 / Accepted: 21 August 2020

### Abstract

**Introduction:** Nowadays, due to a multitude of physical and psychological factors, more and more patients suffer from dental wear. The overlapping of metabolic disorders often leads to oral effects that generate major functional and esthetic inadvertencies, which can be challenging even for experienced clinicians. **Case report:** We present a senior female patient with type 2 diabetes mellitus and severe anterior dental wear associated with poor oral hygiene, periodontal disease, and tooth loss in the posterior dental arches. After general health evaluation, surgical, periodontal and endodontic treatments were conducted, followed by a combined prosthodontic rehabilitation treatment plan which involved the conventional and digital fabrication of dental restorations. **Conclusions:** Clinical results showed that the esthetic and functional outcome of the treatment was achieved even when combining the two methods (digital and conventional) of fabricating dental restorations and the so-called sixth complication of diabetes, the periodontal disease was diminished, due to optimal hygiene allowed by the design of the restorations.

**Keywords:** Type 2 diabetes, severe dental wear, CAD/CAM restorations.

### Introduction

Diabetes has reached the status of being one of the most prevalent noncommunicable diseases of senior people [1]. As a result, the health concerns are serious due to the large number of older patients that require dental treatments that, among other associated health problems, present metabolic diseases. Depending on the type of diabetes, the dental approach needs to undergo specific steps. The prevalence of type 1 diabetes is relatively low compared to the total number of diabetic patients and represents approximately 5% [2]. However, it is estimated that worldwide, 1 out of 11 people have a metabolic disease, out of which 90% fall in the type 2 diabetes (T2D) category [3]. The leading causes of a drastic increase in the T2D cases range from bad eating habits, lack of physical activity, and population aging [4, 5]. One of the main concerns regarding T2D

is represented by the fact that the disease occurrence precedes the diagnosis by several years [6]. This leads to an increased risk of developing complications that impact both the overall health and dental status [7]. T2D reduces the life expectancy of patients and, in association with other risk factors such as genetic predisposition and high body mass index, leads to millions of deaths annually [8, 9].

Another common characteristic of the senior population is represented by the wear of the teeth that are still present in the oral cavity. The progression of the wear is usually constant throughout life and influences the ability to efficiently chew the food [10, 11]. The most common factors that lead to tooth wear are represented by the mechanic grinding of opposing teeth structures (attrition), wear due to contact with structures other than teeth (abrasion), and loss of tooth structure due to chemical agents (erosion) [12, 13].



Although tooth wear starts from an early age, it usually becomes evident in the later stages of life, and in some cases, the development of the process is so advanced that it drastically diminishes the function and esthetics of the teeth [14-16]. The overlapping of metabolic diseases such as T2D, through its influence on teeth supporting structures, may lead to severe tooth mobility, and without a systematic periodontal and prosthodontic treatment, the outcomes will lead to the loss of the afflicted teeth [17].

Prosthetic rehabilitation of patients with T2D and severe anterior tooth wear can be a challenging situation, and this case report illustrates the functional and esthetic outcome achieved with a combination of digital and conventional methods for dental prostheses fabrication.

## Case report

A 63 years old female patient with T2D was addressed to the Department of Prosthodontics of the Faculty of Dentistry from Timisoara, and the main complaint was major esthetic problems in the anterior arch as well as functional problems in the lateral areas.

All papers regarding personal data protection, informed consent for the treatment, and the acceptance for digital photography were signed by the patient, and the medical and dental history was investigated. The anamnesis revealed a T2D metabolic disorder diagnosed at the age of 59, which has never been under rigorous control (HbA1c=7.1%). The main identified cause for the increased glycemic index was the increased daily sugar intake. The physical examination showed a height of 161 cm and a bodyweight of 72 kg with a BMI of 27.8.

During the first appointment, the clinical examination was performed. The extraoral examination showed no evident asymmetries, adequate muscle coordination, medium-high smile line, and accentuated perioral folds due to the decreased vertical dimension of occlusion. There was no visibility of upper anterior teeth in the rest position due to excessive wear (Figure 1). No pain was reported in the temporomandibular joint, the lymph nodes were not palpable, and the

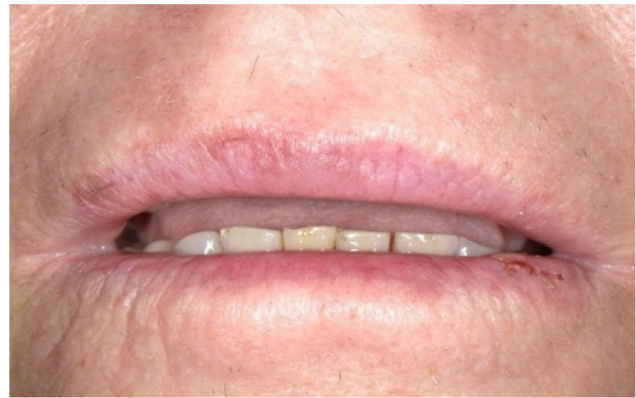

Figure 1: At presentation, in the rest position, there is no visibility of front upper teeth.

mouth opening amplitude was within normal limits.

The intraoral examination revealed gingivitis in the area of mandibular anterior teeth, fixed dental prostheses in the posterior mandible, and wear of all upper anterior teeth (Figure 2).

The main objectives of the treatment were the prosthodontic rehabilitation of the function and the esthetics and also the control of periodontal disease, facilitated through the design of the final restorations.

The first step included a set of preliminary alginate impressions which were poured and mounted in a semi-adjustable articulator (Artex, AmannGirrbach). The occlusal analysis showed increased tooth wear in the upper frontal arch associated with occlusal interferences. A maxillary diagnostic wax-up was manufactured in the dental laboratory with an increased vertical dimension of occlusion (VDO) of 3 mm. Based on this wax-up, direct provisional restorations were

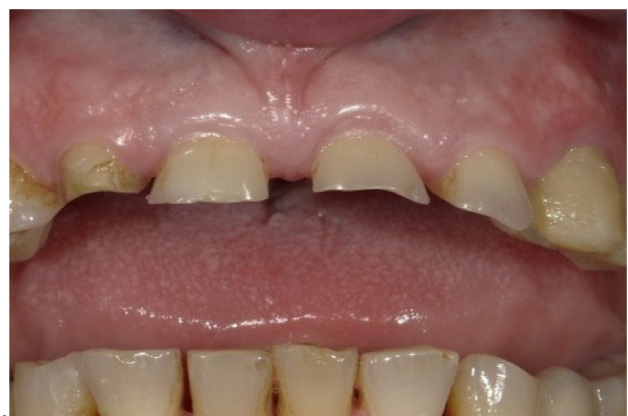

Figure 2: Excessive wear of upper front teeth.

manufactured (Luxatemp, DMG) and assessed for esthetics and acceptance from the patient.

Upon the patient's approval, the second phase of the treatment was initiated, which involved the removal of the old fixed dental prostheses and the periodontal and endodontic treatment of the remaining abutments.

Next, another set of direct provisional restorations was made and set in place with a temporary luting cement for three weeks, allowing the patient to adjust with the increase in the VDO.

A combined conventional and digital treatment plan was chosen. The reason behind the treatment plan was to offer the best possible outcome with the limited financial resources provided by the patient.

For the lateral arches, metal-ceramic fixed partial restorations were placed on the remaining abutments. Due to the old restorations' previous design, the abutments were prepared with a 'no shoulder' finish line. Then, the design of the fixed partial dentures followed the design of the provisional restorations. The final restorations were adjusted and luted with temporary cement. During these stages, the provisional restorations were kept in place on the upper frontal arch.

Next, for the upper front teeth with wear, a minimally invasive approach was implemented, with four rounded shoulder crown preparations on the incisors and a veneer preparation on the canine. Also, the minimal reduction of the teeth surfaces avoided the endodontic treatment (Figure 3).

The preparations were scanned with the intraoral scanner (PlanScan, Planmeca), obtaining the digital model (Figure 4). All the digital design steps were followed, including scanning

the opposing arch and occlusion, placement of the finish lines, and designing the final ceramic restorations (Figure 5).

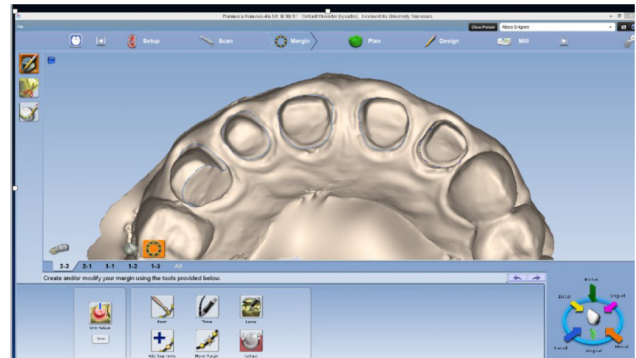


Figure 4: Digital model obtained after intraoral scanning with PlanScan (Planmeca).

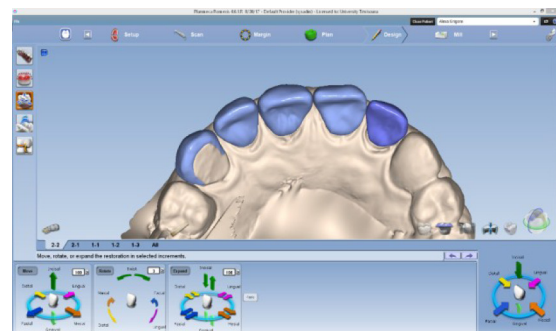
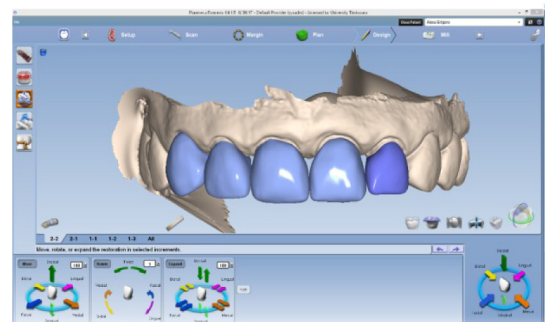


Figure 5: Digital design for one veneer and 4 crowns obtained with PlanCAD Easy (Planmeca).

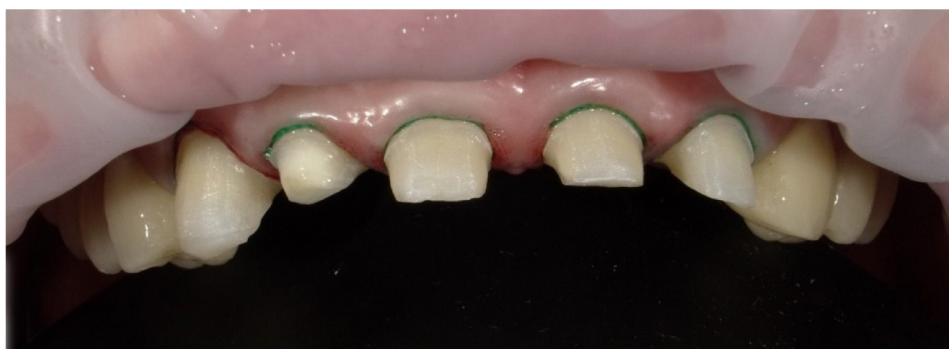

Figure 3: Conservative preparation of the front teeth.

After in-office milling (with Planmill 40, Planmeca) of leucitic ceramic blocks (Empress CAD Multi ceramic blocks) (Figure 6), an initial clinical trial of the restorations was performed, and some minor adjustments were made and then sent for glazing to a dental technician.

Adhesive cementation protocol was conducted with light-curing resin cement (Vario-link Esthetic LC, Ivoclar, Vivadent), and the final result brought satisfaction to the clinician's team and also to the patient.

## Discussion

In general, the patients who suffer from a metabolic disease such as T2D can be treated in the dental office without significant complications. The key to a successful treatment is



Figure 6: Empress CAD multi block, after removal from the milling machine.

the constant check-up of the glycemic values combined with the appropriate medication, the cooperation, and involvement of the patient being of the utmost importance to keep the disease under control [5].

Prosthetic treatment is not necessary in all cases of tooth wear. Factors related to the severity of tooth wear relative to the age of the patient, the etiology, the symptoms, the progression rate, and the patient's expectations should be taken into consideration in the attempt to decide the treatment [18-20]. Metal-ceramic fixed dental prostheses were selected for the lateral area since they seem to be the safest choice in cases of high load conditions. Individual ceramic restorations were selected in the anterior arch because torque forces are minimized. Even if cementation failure occurs, detection and repair would be easier in crowns than in multiple unit bridges, where a single abutment de-cementation is challenging to be detected. Moreover, all-ceramic restorations provide superior esthetic results and sufficient strength as long as the occlusal contacts are adequately balanced.

## Conclusions

Proper occlusal adjustment of the metal-ceramic restorations, a protective stabilization splint, and frequent recall and maintenance visits minimize the incidence of clinical complications. This is even more imperative in the cases of patients who have an overlapped metabolic disease due to its significant influence

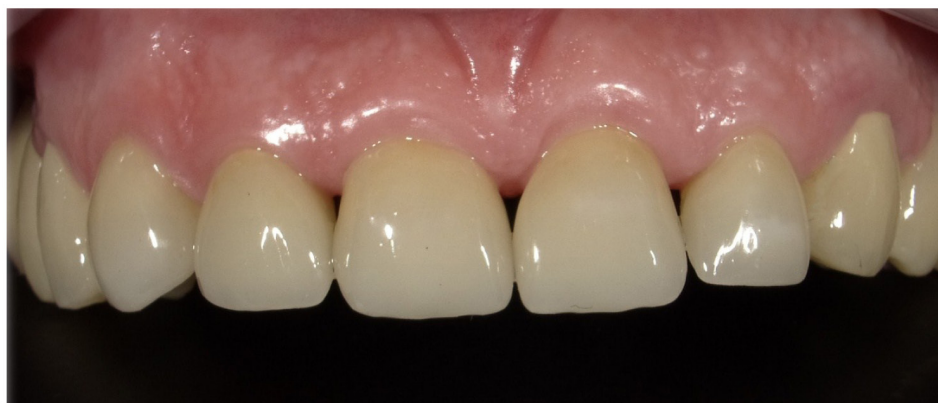

Figure 7: Empress CAD multi ceramic restorations after adhesive cementation on upper front teeth.

on teeth supporting structures. The involvement of the patient in maintaining oral hygiene and also the glycemic values within normal limits is the only way for having long-lasting restorations.

## Conflict of Interest

The authors declare no conflict of interest.

## References

1. K. Denys, M. Cankurtaran, W. Janssens, and M. Petrovic, "Metabolic syndrome in the elderly: an overview of the evidence," *Acta Clinica Belgica*, vol. 64, no. 1, pp. 23–34, 2009.
2. ADA. Classification and diagnosis of diabetes. *Diabetes Care* 40: S11–S24, 2017.
3. International Diabetes Federation. IDF Diabetes Atlas — 7th Edition. *DiabetesAtlas* <http://www.diabetesatlas.org/> (2015).
4. Holman, N., Young, B. & Gadsby, R. Current prevalence of type 1 and type 2 diabetes in adults and children in the UK. *Diabet Med.* 32, 1119–1120 (2015).
5. Bruno, G. et al. Incidence of type 1 and type 2 diabetes in adults aged 30–49 years: the population-based registry in the province of Turin, Italy. *Diabetes Care* 28, 2613–2619 (2005).
6. GBD 2015 Risk Factors Collaborators. Global, regional, and national comparative risk assessment of 79 behavioural, environmental and occupational, and metabolic risks or clusters of risks, 1990–2015: a systematic analysis for the Global Burden of Disease Study 2015. *Lancet* 388, 1659–1724 (2016).
7. NCD Risk Factor Collaboration. Worldwide trends in diabetes since 1980: a pooled analysis of 751 population-based studies with 4.4 million participants. *Lancet* 387, 1513–1530 (2016).
8. GBD 2013 Mortality and Causes of Death Collaborators. Global, regional, and national age-sex specific all-cause and cause-specific mortality for 240 causes of death, 1990–2013: a systematic analysis for the Global Burden of Disease Study 2013. *Lancet* 385, 117–171 (2015).
9. Roglic, G. & Unwin, N. Mortality attributable to diabetes: estimates for the year 2010. *Diabetes Res. Clin. Pract.* 87, 15–19 (2010).
10. R. Omar, A. Johansson, A. K. Johansson, and G. E. Carlsson. "Tooth wear," *International Journal of Dentistry*, vol. 2012, Article ID 731085, 1 pages, 2012.
11. S. B. Mehta, S. Banerji, B. J. Millar, and J. M. Suarez-Feito. "Current concepts on the management of tooth wear: part 1. Assessment, treatment planning and strategies for the prevention and the passive management of tooth wear," *British Dental Journal*, vol. 212, no. 1, pp. 17–27, 2012.
12. S. O'Toole, M. Pennington, S. Varma, and D. W. Bartlett. "The treatment need and associated cost of erosive tooth wear rehabilitation - a service evaluation within an NHS dental hospital," *BDJ*, vol. 224, no. 12, pp. 957–961, 2018.
13. D. W. Bartlett, J. Fares, S. Shirodaria, K. Chiu, N. Ahmad, and M. Sherriff. "The association of tooth wear, diet and dietary habits in adults aged 18–30 years old," *Journal of Dentistry*, vol. 39, no. 12, pp. 811–816, 2011.
14. Liu, M. Zhang, Y. Chen, and Y. Yao. "Tooth wear in aging people: an investigation of the prevalence and the influential factors of incisal/occlusal tooth wear in northwest China," *BMC Oral Health*, vol. 14, no. 1, p. 65, 2014.
15. P. Wetselaar, J. H. Vermaire, C. M. Visscher, F. Lobbezoo, and A. A. Schuller. "The prevalence of tooth wear in the Dutch adult population," *Caries Research*, vol. 50, no. 6, pp. 543–550, 2016.
16. W. Aekplakorn, S. Chariyalertsak, P. Kessomboon, S. Assanangkornchai, S. Taneepanichskul, and P. Putwatana. "Prevalence of diabetes and relationship with socioeconomic status in the 'ai population: national health examination survey, 2004–2014," *Journal of Diabetes Research*, vol. 2018, Article ID 1654530, 8 pages, 2018.
17. Vergnes JN, Canceill T, Vinel A et al. The effects of periodontal treatment on diabetic patients: the DIAPERIO randomized controlled trial. *J Clin Periodontol* 45(10): 1150–1163, 2018.
18. Tzanakakis, Manos & Pepelassi, Eudoxie & Tzoutzas, Ioannis. (2019). *Prosthodontic Rehabilitation of a Mandibular Worn Dentition: A Case Report Case Report Oral Biology*.
19. I. Azouzi, I. Kalghoum, D. Hadyaoui, B. Harzallah & M. Cherif. (2018). Principles and guidelines for managing tooth wear: a Review. *Internal Medicine and Care*. 2. 10.15761/IMC.1000112.
20. Loomans, Bas, Opdam, Niek, & Attin et al. (2017). Severe Tooth Wear: European Consensus Statement on Management Guidelines. *The journal of adhesive dentistry*. 19. 10.3290/j.jad.a38102.